

## Isotretinoin Beyond the Skin: A Prospective Study on Its Impact on Periodontal Health

Funda Erduran<sup>1</sup>, Mehmet Dođuhan oşlu<sup>1</sup>, Seyhan Karaaslan<sup>2</sup>, Selma Emre<sup>3</sup>

**1 Department** of Dermatology, Ankara Bilkent City Hospital, Ankara, Türkiye

**2** Ankara Bilkent City Hospital, Department of Oral and Dental Health, Ankara, Turkey

**3** Ufuk University, Department of Dermatology, Ankara, Turkey

**Key words:** Isotretinoin, Periodontal health, Bleeding on probing, Plaque index, Probing depth

**Citation:** Erduran F, oşlu MD, Karaaslan S, Emre S. Isotretinoin Beyond the Skin: A Prospective Study on Its Impact on Periodontal Health. *Dermatol Pract Concept.* 2026;16(2):6739. DOI: <https://doi.org/10.5826/dpc.1602a6739>

**Accepted:** November 6, 2025; **Published:** April 2026

**Copyright:** ©2026 Erduran et al. This is an open-access article distributed under the terms of the Creative Commons Attribution-NonCommercial License (BY-NC-4.0), <https://creativecommons.org/licenses/by-nc/4.0/>, which permits unrestricted noncommercial use, distribution, and reproduction in any medium, provided the original authors and source are credited.

**Funding:** None.

**Competing Interests:** None.

**Authorship:** All authors have contributed significantly to this publication.

**Corresponding Author:** Funda Erduran, Ankara Bilkent City Hospital, Department of Dermatology, Ankara, Türkiye. ORCID: 0000-0002-3318-2248. E-mail: [fnderdrn@gmail.com](mailto:fnderdrn@gmail.com)

**ABSTRACT** **Background:** Isotretinoin is a systemic retinoid widely used for the treatment of severe acne vulgaris. While its dermatologic side effects are well known, its potential impact on periodontal health has not been fully elucidated.

**Objective:** This prospective study aimed to evaluate the effects of systemic isotretinoin therapy on clinical periodontal parameters in young adults treated for acne vulgaris.

**Methods:** A total of 80 patients (59 females and 21 males), aged between 18 and 25 years, undergoing systemic isotretinoin therapy (0.5 mg/kg/day for months 0–3 and 0.7 mg/kg/day for months 4–6) for a duration of six months, were included in the study. Clinical periodontal assessments, including bleeding on probing (BOP), plaque index (PI), and probing depth (PD), were performed at baseline and after six months. Patients with systemic conditions, recent dental treatments or antibiotic use, and other potential confounding factors were excluded. Data were analyzed using the Wilcoxon signed-rank test, McNemar test, and regression analysis.

**Results:** Posttreatment assessments showed a significant increase in the prevalence of BOP (from 18.8% to 48.8%,  $P<0.001$ ). The mean PI increased from  $1.06 \pm 1.24$  to  $1.26 \pm 1.25$  ( $P=0.007$ ), while the mean PD rose from  $1.25 \pm 1.06$  mm to  $1.73 \pm 1.08$  mm ( $P<0.001$ ). No significant association was found between changes in periodontal parameters and age or sex, as determined by regression analysis.

**Conclusion:** Isotretinoin therapy may contribute to subclinical deterioration in periodontal health, as evidenced by increased BOP, PI, and PD values. Although these changes were modest, clinicians prescribing isotretinoin should consider potential oral health implications and advise patients accordingly. For dermatologists, incorporating basic periodontal screening into routine care may help identify at-risk patients early.

## Introduction

Acne vulgaris is the most common dermatological condition, characterized by the presence of comedones, papules, and pustules [1]. A recent global study reported a general prevalence of acne at 20.5%, with the highest rate observed in the 16–24 age group, reaching 28.3% [2]. The high prevalence of acne vulgaris is associated with exposome factors such as diet, medication use, occupational exposure, environmental pollutants, climatic conditions, and psychosocial and lifestyle-related elements. These exposome factors can impair the skin's natural barrier and microbiota, leading to hyperseborrhea, abnormal keratinization of the pilosebaceous duct, reduced microbial diversity, and inflammation. Interactions among these factors contribute to a localized chronic inflammatory response within the pilosebaceous units [3].

The disease typically affects the face and trunk and presents with noninflammatory lesions (comedones) and inflammatory lesions (papules, pustules, nodules, and cysts), which may resolve with scarring. Consequently, it can significantly impair quality of life. Early, adequate, effective, and safe treatment is crucial to prevent both physical and psychological sequelae of the disease [4].

Various treatment options are available for acne management. First-line therapies include topical agents such as retinoids, azelaic acid, benzoyl peroxide, and combinations of these agents. In more persistent or severe cases, systemic treatments such as oral antibiotics, isotretinoin, or hormonal therapy may be considered [5]. In 1982, the United States Food and Drug Administration (FDA) approved isotretinoin (13-cis-retinoic acid), a vitamin A-derivative retinoid, for the treatment of severe and treatment-resistant acne vulgaris. Oral isotretinoin monotherapy is considered the most effective treatment option for severe acne. Initially, its use was limited to severe forms of nodulocystic acne; however, in recent years, it has also been used off-label in mild-to-moderate acne unresponsive to conventional therapies [6].

Isotretinoin is the only treatment option that targets all major etiological factors involved in the pathogenesis of acne [7]. It does not directly bind to retinoic acid receptors; instead, it is thought to be converted into active metabolites in sebocytes, which then bind to retinoid receptors. Isotretinoin reduces the size of sebaceous glands, decreases sebum production, regulates cell proliferation, and reduces keratinization. It also alters the follicular microenvironment, leading to a reduction in *Cutibacterium acnes* populations [6]. Moreover, isotretinoin exhibits anti-inflammatory and immunomodulatory properties; it minimizes the inflammatory cytokine response by downregulating Toll-like receptor 2 (TLR-2) expression in monocytes [8].

The conventional dosage of isotretinoin is 0.5–1 mg/kg/day, administered in two divided doses, with a standard

cumulative dose of 120–150 mg/kg per course. The management of acne treatment may vary according to different guidelines and consensus reports. European guidelines recommend a daily dose range of 0.3–0.5 mg/kg, whereas American guidelines allow for doses up to 1 mg/kg [9]. The typical duration of treatment is 4–6 months, which can be adjusted based on daily dosage, clinical response, and adverse effects. Treatment discontinuation should be considered if there is more than a 90% improvement in clinical acne severity score compared to baseline, and this improvement is sustained for 1–2 months [6].

Although isotretinoin is an effective and generally well-tolerated medication, it has a broad side effect profile. The most serious and feared adverse effect is teratogenicity [4]. The most common side effects are mucocutaneous and are predictable, dose-dependent, and typically manageable with dose adjustment or symptomatic treatment. While adverse effects that necessitate discontinuation of therapy are rare, they usually resolve after cessation of treatment [7,10]. The most frequently reported mucocutaneous side effects include cheilitis, xerosis, erythema, rash, desquamation, dermatitis, pruritus, epistaxis, mucosal dryness, and dry or irritated eyes [10,11]. Cheilitis is observed in nearly all patients, and its absence may suggest non-compliance or inadequate therapeutic response [10]. An increased incidence of *Staphylococcal* infections has also been reported in patients receiving systemic isotretinoin [12]. Additionally, the stimulation of granulation tissue leading to pyogenic granuloma formation may occur in nail folds, trauma sites, and acne lesions [13]. Other potential side effects include elevated lipid and cholesterol levels, increased liver enzymes, the onset or exacerbation of inflammatory bowel disease, night blindness, hyperostosis, premature epiphyseal closure, myalgia, and neuropsychiatric effects such as depression, psychosis, and suicidal ideation [10,11,14].

Although the mucocutaneous side effects of systemic isotretinoin therapy suggest a potential link to the development of periodontal diseases [4,10,11], there is a notable lack in the literature of in-depth and comprehensive studies on this topic. Clinical parameters commonly used in the evaluation of periodontal tissues include bleeding on probing (BOP), which indicates inflammation, and probing depth (PD), which measures pocket depth. The plaque index (PI) is used to assess plaque accumulation [15,16]. The PI is particularly important for evaluating oral hygiene and investigating its association with BOP; higher PI scores are correlated with increased bleeding [15,16].

## Objectives

The aim of this study was to evaluate the periodontal changes observed in patients undergoing systemic isotretinoin therapy.

## Materials and Methods

This prospective study was initiated following the approval of the Ethics Committee of Ankara Bilkent City Hospital (approval number: E1-23-3714, dated 12 July 2023). Between August 2023 and February 2025, patients aged 18 to 25 years who were being followed in our clinic for acne vulgaris and had been using systemic isotretinoin for at least six months were included in the study. Patients were excluded if they had received dental treatment or used antibiotics within the preceding month, were smokers, had a history of long-term medication use that could affect periodontal status, or had metabolic disorders, autoimmune diseases, diabetes, or were pregnant. Additionally, patients who failed to maintain compliance with inclusion and exclusion criteria during the study period were withdrawn from the study. Informed consent was obtained from all patients who agreed to participate. The study was conducted in accordance with the latest version of the Declaration of Helsinki. The study workflow is summarized in Figure 1.

### Periodontal Examination

The reliability of periodontal parameter measurements was tested prior to the study. Following the initial evaluations of 18 randomly selected patients not involved in the study, repeated periodontal measurements were conducted within 24 hours. The kappa values for repeated periodontal measurements were found to be above 0.80, indicating high reliability. The assessments included the PI, PD, and BOP. PD was measured in millimeters as the distance from the gingival margin to the base of the periodontal pocket, using a standardized probing pressure. BOP was recorded based on the presence or absence of bleeding at the probed sites within 60 seconds after probing.

Measurements were performed using a periodontal probe (Hu-Friedy Co., Chicago, IL, USA) at six sites per tooth, excluding third molars: mesiobuccal, mid-buccal, distobuccal, mesiolingual, mid-lingual, and distolingual. Clinical probing depth was evaluated at 125 points across 27 teeth (from 27 subjects) and compared with posttreatment tissue levels using a probing force of 0.25 N.

PI scores were recorded using the Silness and Løe plaque index [17,18]. For this examination, teeth were first isolated

using cotton rolls and then air-dried. The amount of plaque near the gingival margin on each tooth was assessed using a periodontal probe, without the use of any plaque-disclosing agents. Index scores ranging from 0 to 3 were assigned based on the amount of plaque observed at three points on the mesial, mid, and distal aspects of the buccal surface, and one point on the lingual/palatal surface.

The PI was recorded using the following criteria: a score of 0 indicated the absence of visible plaque; a score of 1 represented the presence of a thin film of plaque along the gingival margin, detectable with a periodontal probe; a score of 2 denoted a moderate accumulation of plaque along the gingival margin, visible to the naked eye; and a score of 3 indicated heavy plaque accumulation that was clearly visible along the gingival margin, with deposits extending into and filling the interdental spaces.

PD was measured using a periodontal probe (UNC 15, Hu-Friedy, USA). The probe was gently inserted along the long axis of the tooth to the base of the periodontal pocket until optimal resistance was felt. The distance from the base of the pocket or sulcus to the gingival margin was measured and recorded. Measurements were taken from the mesio-buccal, mid-buccal, distobuccal, and mid-palatal/lingual surfaces of the teeth.

Patients who underwent a baseline periodontal examination prior to treatment were subsequently started on systemic isotretinoin therapy at a dose of 0.5 mg/kg/day and were followed throughout the treatment period. During this time, patients were advised to maintain their personal oral hygiene practices in the same manner as before treatment. To ensure standardization, all patients received isotretinoin at a dose of 0.5 mg/kg/day for the first three months, followed by 0.7 mg/kg/day for the subsequent three months. At the end of the 6-month treatment period, periodontal examinations were repeated.

### Statistical Analysis

Data analysis was performed using the SPSS software version 11.5. Descriptive statistics are presented as mean  $\pm$  standard deviation (SD) and median (minimum–maximum) for quantitative variables, and as number (percentage) for qualitative variables. The McNemar test was used to assess differences between two dependent categorical variables. The Wilcoxon

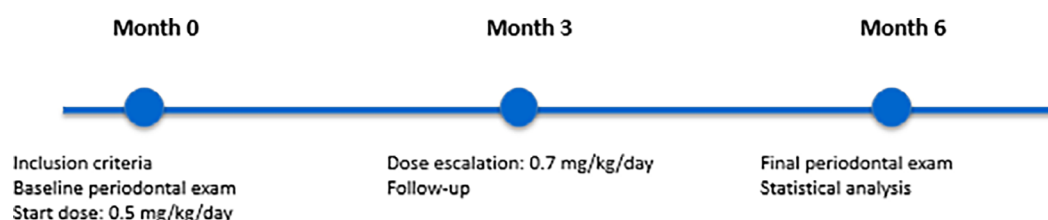


Figure 1. Timeline diagram of the study design.

signed-rank test was used to evaluate differences between two dependent quantitative variables. Factors influencing a dependent quantitative variable were assessed using univariate linear regression analysis, while factors influencing a dependent categorical variable were assessed using univariate logistic regression analysis. A p-value of less than 0.05 was considered statistically significant.

## Results

A total of 23 patients were excluded from the study due to personal reasons such as relocation to another city, inability to attend hospital visits, or discontinuation of treatment. The study was completed with 80 patients, including 59 females (73.8%) and 21 males (26.2%). The mean age of the participants was  $21.50 \pm 1.99$  years (range: 18–25). The age and sex distribution of the patients is presented in Table 1.

### Periodontal Parameters

#### BOP

Before treatment, BOP was present in 15 patients (18.8%), whereas after treatment, it was detected in 39 patients (48.8%). A significant difference was found between the pre- and posttreatment BOP prevalence rates ( $P < 0.001$ ). Among the patients who did not have BOP before treatment, 38.5% exhibited BOP after treatment. Additionally, 93.3% of patients with pretreatment BOP continued to have BOP post-treatment. Only one patient with pretreatment BOP showed no BOP following treatment. The changes in BOP before and after treatment are presented in Table 2.

**Table 1. Age and sex characteristics of the patients.**

Total number of patients (N)	80
Female (%)	59 (73.8)
Male (%)	21 (26.2)
Mean age (years) ( $\pm$ SD)	$21.50 \pm 1.99$
Age range (years) (min–max)	18 – 25

SD: standard deviation; Min: minimum; Max: maximum

**Table 2. Changes in bleeding on probing (BOP) before and after treatment.**

BOP N (%)		Pretreatment		p-value
		Absent	Present	
Posttreatment	Absent	40 (61.5)	1 (6.7)	$<0.001^a$
	Present	25 (38.5)	14 (93.3)	

BOP: bleeding on probing; <sup>a</sup>:Mc-Nemar test

#### PI and PD

The mean PI before treatment was  $1.06 \pm 1.24$ , which increased to  $1.26 \pm 1.25$  after treatment. A significant difference was observed between pre- and posttreatment PI values ( $P = 0.007$ ).

The mean PD before treatment was  $1.25 \pm 1.06$ , which increased to  $1.73 \pm 1.08$  after treatment. A significant difference was found between pre- and posttreatment PD values ( $P < 0.001$ ).

Changes in PI and PD before and after treatment are presented in Table 3.

#### Changes in BOP, PI, and PD Before and After Treatment

After treatment, 67.5% of patients showed no change in BOP, while 1.3% exhibited a decrease and 31.3% showed an increase. The mean difference between pre- and posttreatment PI values was  $0.20 \pm 0.70$ , and the mean difference for PD was  $0.49 \pm 0.59$  mm. Overall, an increase in BOP, PI, and PD values was observed in patients following treatment (Figure 2, Table 4).

#### Regression Analysis of BOP, PI, and PD Values with Age and Sex Variables

The potential effects of age and sex on changes in BOP, PI, and PD values were analyzed through regression analyses. The results revealed no statistically significant impact of either age or sex on any of these periodontal parameters, as detailed in Tables 5–7.

## Discussion

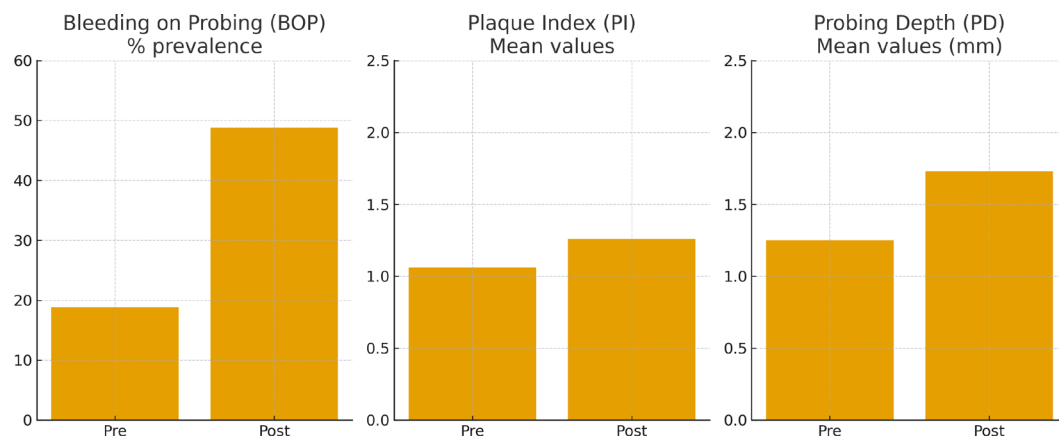
In the current study, we compared the clinical periodontal parameters of patients receiving systemic isotretinoin treatment for acne before treatment and after six months of therapy. To better isolate the effect of the drug by eliminating confounding factors, we standardized the age range to 18–25 years and the treatment dosage to 0.5 mg/kg for the first three months, followed by 0.7 mg/kg for the subsequent three months. Measurements before and after treatment were performed by the same investigator on the same patients. While the prevalence of BOP was found to be significantly increased after treatment, the PI and probing depth PD values were also significantly elevated. There is a notable scarcity of studies in the literature examining the effects of systemic isotretinoin on periodontal health [19–22].

AlJasser et al. investigated the relationship between systemic isotretinoin use and salivary levels of tissue metalloproteinase inhibitors (TIMP-1 and TIMP-2), reporting significantly higher concentrations of both biomarkers in isotretinoin users compared to non-users. Given the anti-inflammatory properties of TIMP-1 and TIMP-2, these

**Table 3. Changes in plaque index (PI) and probing depth (PD) before and after treatment.**

Variables	Time	Mean ± SD	Median (Min–Max)	p-value
PI	Pretreatment	1.06±1.24	0.00 (0.00-3.00)	0.007 <sup>a</sup>
	Posttreatment	1.26±1.25	1.00 (0.00-3.00)	
PD	Pretreatment	1.25±1.06	1.00 (0.00-5.00)	<0.001 <sup>a</sup>
	Posttreatment	1.73±1.08	1.63 (0.00-5.00)	

PI: plaque index; PD: probing depth; SD: standard deviation; Min: minimum; Max: maximum; <sup>a</sup>: Wilcoxon signed-rank test



**Figure 2.** Bar graphs summarizing changes in BOP, PI, and PD before and after isotretinoin treatment.

**Table 4. Descriptive statistics of changes in BOP, PI, and PD before and after treatment.**

Variables		
BOP Change, N (%)	No Change	54 (67.5)
	Decrease	1 (1.3)
	Increase	25 (31.3)
PI Difference (Pre-Post)	Mean ± SD	0.20±0.70
	Median (Min–Max)	0,00 (-3.00-3.00)
PD Difference (Pre-Post)	Mean ± SD	0.49±0.59
	Median (Min–Max)	0.13 (0.00-2.00)

BOP: bleeding on probing; PI: plaque index; PD: probing depth; SD: standard deviation; Min: minimum; Max: maximum

**Table 5. Results of univariate logistic regression analysis for factors affecting changes in BOP.**

Variables (Reference)		OR	95% CI		p value
			Lower limit	Upper limit	
Female	Male	1.484	0.521	4.227	0.460
Age		1.030	0.812	1.307	0.805

OR: odds ratio; CI: confidence interval

**Table 6. Results of univariate linear regression analysis for factors affecting changes in PI.**

Variables	$\beta$	SE	95% CI		p value
			Lower limit	Upper limit	
Sex	-0.013	0.179	-0.370	0.344	0.943
Age	-0.022	0.040	-0.101	0.057	0.576

SE: standard error; CI: confidence interval

**Table 7. Results of univariate linear regression analysis for factors affecting changes in PD.**

Variables	$\beta$	SE	95% CI		p value
			Lower limit	Upper limit	
Sex	0.017	0.151	-0.283	0.317	0.911
Age	-0.042	0.033	-0.108	0.024	0.207

SE: standard error; CI: confidence interval

findings were interpreted as indicative of a potential protective effect of isotretinoin on periodontal health. A key limitation, however, was that data were collected at a single time point, without prospective follow-up [19].

In a subsequent study, AlJasser et al. evaluated changes in clinical periodontal parameters and salivary levels of matrix metalloproteinases (MMP-8 and MMP-9) in patients receiving isotretinoin for at least three months for acne treatment, including individuals with varying stages of periodontal disease, and compared them to periodontally healthy controls. Among patients with gingivitis and periodontitis, isotretinoin use was associated with significantly lower BOP values, while periodontitis patients on isotretinoin also exhibited significantly lower MMP-8 and MMP-9 levels compared to non-users. The authors concluded that isotretinoin might attenuate both clinical and biological markers of inflammation involved in periodontal disease progression. Nevertheless, the case-control design and cross-sectional data collection remained important limitations [20].

In another case-control study by AlJasser et al., the oral microbial profile of isotretinoin users was analyzed. Levels of *Porphyromonas gingivalis*, *Tannerella forsythia*, and *Treponema denticola* were significantly lower, whereas *Fusobacterium nucleatum* levels were significantly higher, in the isotretinoin group ( $P < 0.001$ ). The authors suggested that isotretinoin may exert a measurable antimicrobial effect on periodontal pathogens in patients with plaque-induced gingivitis and chronic periodontitis. However, similar to their earlier work, data were collected only once, limiting the strength of the conclusions [21].

Although the studies by AlJasser et al. [19-21] suggested a potential protective or antimicrobial effect of isotretinoin on periodontal health, several methodological differences may explain the discrepancy with our findings. First, their investigations were primarily cross-sectional or case-control

in design, whereas ours was a prospective study assessing intra-individual changes over a six-month treatment period. Second, they included heterogeneous populations with varying periodontal status, while our study focused exclusively on periodontally healthy young adults, which may yield different baseline responses. Third, while AlJasser et al. emphasized salivary biomarkers (TIMP-1, TIMP-2, MMP-8, MMP-9) and single-point clinical assessments, we directly evaluated longitudinal changes in standard periodontal indices (BOP, PI, and PD). These distinctions in study design, population, and outcome definitions may account for the contrasting results.

Majahan et al. reported a clinical case supporting our results [22]. They described a 19-year-old female who developed persistent, severe, non-plaque-induced gingivitis while receiving isotretinoin (10 mg/day) for nodular acne over a six-month period. No alternative etiology was identified, and complete resolution occurred only after isotretinoin cessation and subsequent periodontal therapy. The case was therefore classified as isotretinoin-associated gingivitis [22].

In a study conducted by Shibuya et al., the effects of retinoic acid on the differentiation of periodontal ligament cells were investigated. The periodontal ligament is a cellular connective tissue situated between the tooth roots and alveolar bone. Periodontitis may be associated with inflammation of the periodontal ligament. This study demonstrated that retinoic acid inhibited mineralization in periodontal ligament cell cultures in a dose-dependent manner, with stronger inhibition observed during the early stages. It was proposed that retinoic acid acts as a potential negative regulator of human periodontal ligament cell differentiation. The results of this in vitro study may support the findings of our research [23].

In a study by Ustaoglu et al., similar to ours, the effects of isotretinoin treatment on periodontal tissues and salivary oxidative stress markers were assessed. No significant

change was observed in clinical periodontal parameters or oxidative stress markers before and after six months of treatment; however, total antioxidant capacity (TAC) levels were significantly reduced at six months compared to baseline ( $P=0.001$ ). The authors suggested that such alterations in oxidative stress regulation may contribute to the pathological mechanisms underlying isotretinoin's adverse effects. The small sample size—only 18 patients—was noted as the main limitation of the study [24]. Yorulmaz Demir et al. also reported that isotretinoin increases free radical production and decreases TAC [25]. Considering the data from these two studies, one possible mechanism by which isotretinoin adversely affects periodontal health is through oxidative stress, which may contribute to cellular damage, collagen degradation, and tissue destruction in periodontal tissues. Additionally, xerostomia and reduced salivary flow impair mechanical cleansing and antimicrobial defense, potentially increasing the risk of periodontal disease [26]. Another mechanism may involve retinoic acid's impact on keratinocyte differentiation and epithelial cell turnover, which disrupts the integrity of the mucosal barrier. This disruption may facilitate bacterial invasion into periodontal tissues, thereby predisposing to periodontitis [27,28].

### Study Limitations

A major limitation of our study is the relatively small sample size. However, given the challenges of conducting a long-term follow-up of at least six months and patient attrition due to relocation or other personal reasons during the study period, we believe the sample size cannot be considered insufficient. Although an a priori sample size calculation was not performed, a post hoc power analysis was conducted. The analysis indicated that the study had 71% power for detecting changes in PI, 100% power for PD, and 98% power for BOP, at a two-sided significance level of 0.05. These findings suggest that the sample size of 80 patients was sufficient to reliably detect medium-to-large effects, although smaller differences may have been underpowered.

Another limitation of our study is that oral hygiene practices were only self-reported as unchanged during the study period but were not objectively monitored or reinforced. Therefore, lack of control over individual patient behaviors may have partially confounded the observed changes in periodontal parameters. A further limitation is the absence of a posttreatment follow-up period to assess whether the observed periodontal changes were reversible after cessation of isotretinoin therapy. Without such longitudinal data, it remains unclear whether these alterations represent transient, drug-related effects or sustained periodontal deterioration. Future studies with extended posttreatment monitoring are warranted to clarify the long-term clinical implications.

## Conclusion

In conclusion, our findings suggest that systemic isotretinoin therapy may adversely affect periodontal health by altering clinical periodontal parameters. Clinicians are encouraged to remain vigilant regarding these potential oral side effects, particularly in patients with preexisting periodontal risk factors, and to consider incorporating routine periodontal monitoring into the treatment plan. Given the limited evidence in the existing literature, we believe our study offers meaningful insight into this underexplored area; however, further large-scale and long-term studies are needed to confirm and extend these findings.

## References

1. Van Steensel MAM. The genetics of acne. *Ann Hum Genet.* 2025 Jul 21. DOI: 10.1111/ahg.70014
2. Saurat JH, Halioua B, Baissac C, et al. Epidemiology of acne and rosacea: A worldwide global study. *J Am Acad Dermatol.* 2024 May;90(5):1016-1018. DOI: 10.1016/j.jaad.2023.12.038
3. Cong TX, Hao D, Wen X, Li XH, He G, Jiang X. From pathogenesis of acne vulgaris to anti-acne agents. *Arch Dermatol Res.* 2019 Jul;311(5):337-349. DOI: 10.1007/s00403-019-01908-x
4. Bagatin E, Costa CS. The use of isotretinoin for acne - an update on optimal dosing, surveillance, and adverse effects. *Expert Rev Clin Pharmacol.* 2020 Aug;13(8):885-897. DOI: 10.1080/17512433.2020.1796637
5. Mohsin N, Hernandez LE, Martin MR, Does AV, Nouri K. Acne treatment review and future perspectives. *Dermatol Ther.* 2022 Sep;35(9):e15719. DOI: 10.1111/dth.15719
6. Paichitrojjana A, Paichitrojjana A. Oral Isotretinoin and Its Uses in Dermatology: A Review. *Drug Des Devel Ther.* 2023 Aug 25;17:2573-2591. DOI: 10.2147/DDDT.S427530
7. Sadeghzadeh-Bazargan A, Ghassemi M, Goodarzi A, Roohaninasab M, Najari Nobari N, Behrangi E. Systematic review of low-dose isotretinoin for treatment of acne vulgaris: Focus on indication, dosage, regimen, efficacy, safety, satisfaction, and follow up, based on clinical studies. *Dermatol Ther.* 2021 Jan;34(1):e14438. DOI: 10.1111/dth.14438
8. Dispenza MC, Wolpert EB, Gilliland KL, et al. Systemic isotretinoin therapy normalizes exaggerated TLR-2-mediated innate immune responses in acne patients. *J Invest Dermatol.* 2012 Sep;132(9):2198-205. DOI: 10.1038/jid.2012.111
9. Dessinioti C, Zouboulis CC, Bettoli V, Rigopoulos D. Comparison of guidelines and consensus articles on the management of patients with acne with oral isotretinoin. *J Eur Acad Dermatol Venereol.* 2020 Oct;34(10):2229-2240. DOI: 10.1111/jdv.16430
10. Brelford M, Beute TC. Preventing and managing the side effects of isotretinoin. *Semin Cutan Med Surg.* 2008 Sep;27(3):197-206. DOI: 10.1016/j.sder.2008.07.002
11. Brzezinski P, Borowska K, Chiriac A, Smigielski J. Adverse effects of isotretinoin: A large, retrospective review. *Dermatol Ther.* 2017 Jul;30(4). DOI: 10.1111/dth.12483
12. Leyden JJ, James WD. Staphylococcus aureus infection as a complication of isotretinoin therapy. *Arch Dermatol.* 123:606-608, 1987 13.

13. Exner JH, Dahod S, Pochi PE. Pyogenic granuloma-like acne lesions during isotretinoin therapy. *Arch Dermatol*. 1983;119:808-811.
14. Ruchitha S, Gupta N, Singh K. Exploring the multifaceted side effects of isotretinoin: a deep dive into case reports and observational studies. *Arch Dermatol Res*. 2025 Feb 26;317(1):499. DOI: 10.1007/s00403-025-04019-y
15. Heitz-Mayfield LJA. Conventional diagnostic criteria for periodontal diseases (plaque-induced gingivitis and periodontitis). *Periodontol 2000*. 2024 Jun;95(1):10-19. DOI: 10.1111/prd.12579
16. Ito H, Numabe Y, Hashimoto S, et al. Correlation Between Gingival Crevicular Fluid Hemoglobin Content and Periodontal Clinical Parameters. *J Periodontol*. 2016 Nov;87(11):1314-1319. DOI: 10.1902/jop.2016.160092
17. Silness J, Loe H. Periodontal disease in pregnancy. II. Correlation between oral hygiene and periodontal condition. *Acta Odontol Scand*. 1964 Feb;22:121-35. DOI: 10.3109/00016356408993968
18. Loe H. The gingival index, the plaque index and the retention index Systems. *J Periodontol*. 1967;38:Suppl:610-6.
19. AlJasser R, AlAqeely R, AlKenani M, AlQahtani S, AlZahrani A, Lambarte R. The effect of systemic Isotretinoin on salivary tissue inhibitors of metalloproteinases 1 and 2 and salivary flow rate in periodontal disease. *Saudi J Biol Sci*. 2022 Jan;29(1):148-153. DOI: 10.1016/j.sjbs.2021.08.079
20. AlJasser RN, AlAqeely RS, Al-Hoqail IA, et al. Association between isotretinoin (Roaccutane) use and changes in periodontal clinical parameters and MMP-8 and MMP-9 salivary levels. *Front Biosci (Landmark Ed)*. 2021 Jul 30;26(7):191-197. DOI: 10.52586/4933
21. AlJasser R, AlAqeely R, AlZahrani A, et al. Antimicrobial Effect of Isotretinoin Therapy on Periodontal Pathogens: A Case-Control Study. *Antibiotics (Basel)*. 2021 Oct 21;10(11):1286. DOI: 10.3390/antibiotics10111286
22. Mahajan A, Bharadwaj A, Mahajan P. Non-Plaque-Induced Gingivitis Associated With Isotretinoin: A Case Report. *Clin adv periodontics*. 2011;1(3):205-9.
23. Shibuya N, Nemoto E, Kanaya S, Kunii R, Shimauchi H. Retinoic acid is a potential negative regulator for differentiation of human periodontal ligament cells. *J Periodontol Res*. 2005 Dec;40(6):432-440. DOI: 10.1111/j.1600-0765.2005.00811.x
24. Ustaoglu G, Güler Ş, Polat M. Effect of isotretinoin on periodontal tissues and oxidative stress markers in the saliva. *Turkderm-Turk Arch Dermatol Venereol*. 2020;54(4):132-137. DOI:10.4274/turkderm.galenos.2020.99896
25. Yorulmaz Demir A, Metin A, Işıkoğlu S, Erel Ö. The effect of isotretinoin on oxidative stress in severe acne vulgaris patients. *Türkiye Klinikleri J Med Sci*. 2012;32:1026-1031.
26. Lyng Pedersen AM, Belstrøm D. The role of natural salivary defences in maintaining a healthy oral microbiota. *J Dent*. 2019 Jan;80 Suppl 1:S3-S12. DOI: 10.1016/j.jdent.2018.08.010
27. Fisher GJ, Voorhees JJ. Molecular mechanisms of retinoid actions in skin. *FASEB J*. 1996 Jul;10(9):1002-13. DOI: 10.1096/fasebj.10.9.8801161
28. Kautsky MB, Fleckman P, Dale BA. Retinoic acid regulates oral epithelial differentiation by two mechanisms. *J Invest Dermatol*. 1995 Apr;104(4):546-53. DOI: 10.1111/1523-1747.ep12606058