

## Co-localization of nevus depigmentosus with café au lait macules: Pigmentary twin spotting?

Srishti Dabas<sup>1</sup>, Soumya Narula<sup>1</sup>

<sup>1</sup> Department of Dermatology, Venereology and Leprosy, Maulana Azad Medical College and Lok Nayak Hospital, New Delhi, India

**Citation:** Dabas S, Narula S. Co-localization of nevus depigmentosus with café au lait macules: Pigmentary twin spotting? *Dermatol Pract Concept.* 2026;16(2):6428. DOI: <https://doi.org/10.5826/dpc.1602a6428>

**Accepted:** September 7, 2025; **Published:** April 2026

**Copyright:** ©2026 Dabas et al. This is an open-access article distributed under the terms of the Creative Commons Attribution-NonCommercial License (BY-NC-4.0), <https://creativecommons.org/licenses/by-nc/4.0/>, which permits unrestricted noncommercial use, distribution, and reproduction in any medium, provided the original authors and source are credited.

**Funding:** None.

**Competing Interests:** None.

**Authorship:** All authors have contributed significantly to this publication.

**Corresponding Author:** Soumya Narula, MD, Department of Dermatology, Maulana Azad Medical College and Lok Nayak Hospital, New Delhi, India. E-mail: [soumya.narula17@gmail.com](mailto:soumya.narula17@gmail.com)

### Case Presentation

A 21-year-old woman presented with complaints of hypopigmented lesions over right side of her face since infancy along with gradually progressive hyperpigmented lesions over the same side since nearly 15 years of age. On examination, multiple discreet to confluent, irregular, hypopigmented macules were present over right side of the face, overlying which, multiple irregularly shaped hyperpigmented macules were also noted along with few scattered freckles (Figure 1A). Dermoscopy (Heine Delta 20T, 10x) of hypopigmented lesions revealed white structureless areas (Figure 1B) and from hyperpigmented lesions showed dark brown reticular pattern of pigmentation with brown dots (Figure 1C).

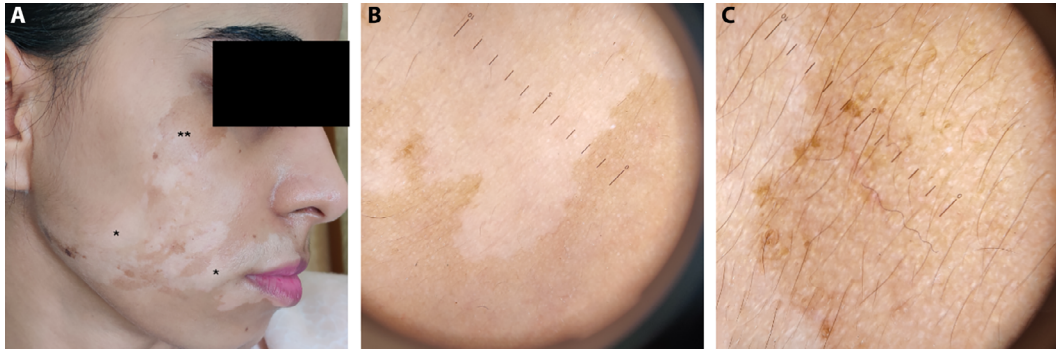
The patient did not reveal any similar history in other family members. Systemic examination was non-significant. Hence a final diagnosis of twin spotting of nevus depigmentosus with café au lait macule was made.

### Teaching Points

Naevus depigmentosus is a disorder of hypomelanosis through postzygotic somatic mutations, resulting in reduced melanogenic potential in a clone of cells during embryogenesis [1]. Café au lait macules (CALMs) are brown coloured maculae with increased melanin and melanocytes within the epidermis. They can be seen sporadically and in association with several genetic syndromes such as neurofibromatosis 1 and Legius syndrome [1].

Twin spotting refers to the presence of adjacent clones of genetically different cells in a background of normal cells producing different phenotypes. It has been hypothesized that these lesions have separate recessive genetic mutations occurring on the same chromosome [2].

Hereby we report an interesting and rare presentation of CALMs and Naevus depigmentosus co-localizing on right side of the face which suggests twin spotting.



**Figure 1.** A) Hyperpigmented (\*\*\*) macules suggestive of CALMs and hypopigmented (\*) suggestive of naevus depigmentosus over ipsilateral side of the face. B) and C) Dermoscopy from naevus depigmentosus and CALM showing white structureless areas and dark brown reticular pattern of pigmentation with brown dots respectively (Heine Delta 20T, 10x).

## References

1. Zhang LW, Wu J. Multiple Hypo- and Hyper-Pigmentation: An Example of Twin Spotting?. *Indian J Dermatol.* 2022;67(6): 755-756. DOI:10.4103/ijd.ijd\_651\_21
2. Afsar FS, Aktas S, Ortac R. Becker's naevus and segmental naevus depigmentosus: an example of twin spotting?. *Australas J Dermatol.* 2007;48(4):224-226. DOI:10.1111/j.1440-0960.2007.00391.x