

## Image Letter

### Multiple Onychopapillomas in a patient with a BAP1 Tumor Predisposition Syndrome.

Anna Słomiak-Wąsik<sup>1</sup>, Katarzyna Korecka<sup>2</sup>

1 Centrum Medyczne Zwierzyniecka, Poznań, Poland

2 Department of Dermatology and Venereology, Poznań University of Medical Sciences, Poznań, Poland

**Citation:** Słomiak-Wąsik A, Korecka K. Multiple Onychopapillomas in a patient with a BAP1 Tumor Predisposition Syndrome. *Dermatol Pract Concept*. 2026;16(2):6146. DOI:

<https://doi.org/10.5826/dpc.1602a6146>

**Accepted:** April 30, 2025; **Published:** April 2026

**Copyright:** ©2026 Słomiak-Wąsik et al. This is an open-access article distributed under the terms of the Creative Commons Attribution-NonCommercial License (BY-NC-4.0), <https://creativecommons.org/licenses/by-nc/4.0/>, which permits unrestricted noncommercial use, distribution, and reproduction in any medium, provided the original authors and source are credited.

**Funding:** None.

**Competing interests:** None.

**Authorship:** All authors have contributed significantly to this publication.

**Corresponding author:** Anna Słomiak-Wąsik, MD, Centrum Medyczne Zwierzyniecka, Poznań, Poland. E-mail: [anna.slomiak@gmail.com](mailto:anna.slomiak@gmail.com)

### Case presentation

A 39-year-old patient presented to the dermatology clinic for a dermatology evaluation after noticing a new lesion on his chest. He had a history of chromophobe renal cell carcinoma and tested positive for a pathogenic variant in a BRCA1-associated protein (BAP1) gene. The patient also reported a family history of melanoma and pleural mesothelioma. On examination of the hands, multiple longitudinal erythro-leukonychias were observed on nearly all fingers. Dermatoscopic examination of the free edges revealed hyperkeratotic plugs beneath the nail plates. Based on these findings, a diagnosis of multiple onychopapillomas was set.

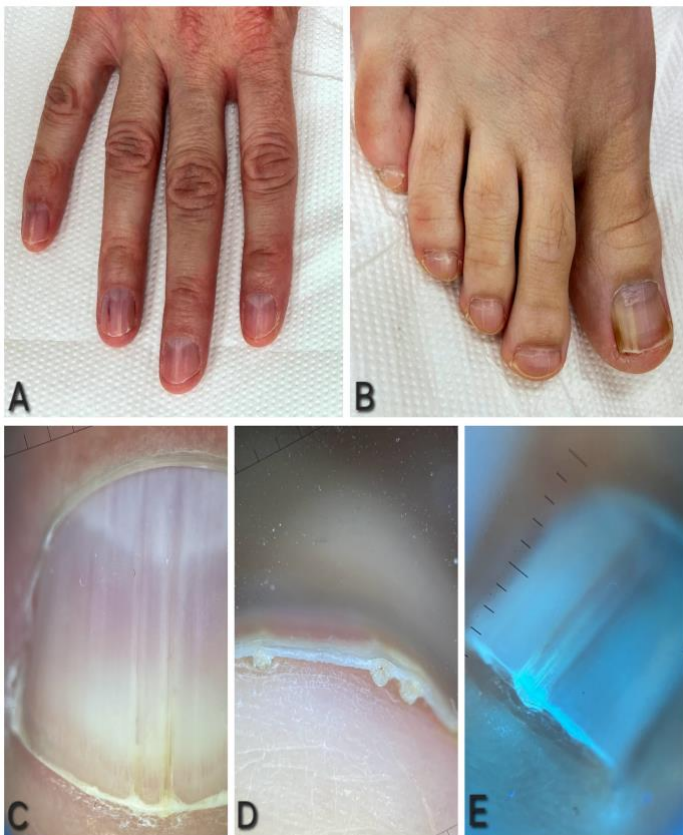
### Teaching Point

Onychopapilloma is a benign tumour of the nail bed which usually presents as a longitudinal erythro-leukonychia with splitting hemorrhages [1]. The distal free edge examination adds clinical information that's relevant to set a correct diagnosis [1,2]. Onychopapilloma is usually a tumor that does not require surgical excision, however, in some doubtful cases a biopsy might be conducted.

Multiple onychopapillomas associated with a BAP1 Tumor Predisposition syndrome were described in the literature only in a study by Lebensohn et al. [1]. The authors examined 47 BAP1 positive patients, in which 39 of them presented onychopapillomas. Interestingly, in 38 subjects, multiple nails were affected. Therefore, we suggest that findings of multiple onychopapillomas in a patient with no history of cancer, should increase vigilance for cancer screening, and potentially testing for BAP1, also within the close family of the patient, as this mutation which may be associated with multiple malignancies such as melanoma, malignant mesothelioma, or kidney carcinoma [1].

## References

1. Lebensohn A, Ghafoor A, Bloomquist L, Royer MC, Castelo-Soccio L, Karacki K, Hathaway O, Maglo T, Wagner C, Agra MG, Blakely AM, Schrupp DS, Hassan R, Cowen EW. Multiple Onychopapillomas and BAP1 Tumor Predisposition Syndrome. *JAMA Dermatol.* 2024 Aug 1;160(8):838-845. DOI: 10.1001/jamadermatol.2024.1804
2. Lallas A, Korecka K, Apalla Z, Sgouros D, Liopyris K, Argenziano G, Thomas L. Seven Plus One Steps to Assess Pigmented Nail Bands (Melanonychia Striata Longitudinalis). *Dermatol Pract Concept.* 2023 Oct 1;13(4):e2023204. DOI: 10.5826/dpc.1304a204.



**Figure 1.** A, B: Multiple longitudinal leukonychia affecting both fingernails and toenails. C: Numerous lesions also observed within a single nail plate. D: Dermoscopy of the distal nail edge confirms the diagnosis of onychopapilloma. E: UV dermoscopy highlights hyperkeratotic plugs under the nail plate.

