

## Image Letter

### A Rare Clustering of Pigmented Lesions over abdomen

Gitesh Sawatkar<sup>1</sup>, Farhana Mullaveettil<sup>1</sup>, Keshavamurthy Vinay<sup>2</sup>

1 Department of Dermatology and Venereology, All India Institute of Medical Sciences (AIIMS), Nagpur, India

2 Department of Dermatology, Venereology and Leprology, Postgraduate Institute of Medical Education and Research; Chandigarh, India

**Citation:** Sawatkar G, Mullaveettil F, Vinay K. A Rare Clustering of Pigmented Lesions over abdomen. *Dermatol Pract Concept*. 2026;16(2):6074. DOI: <https://doi.org/10.5826/dpc.1602a6074>

**Accepted:** May 28, 2025; **Published:** April 2026

**Copyright:** ©2026 Sawatkar et al. This is an open-access article distributed under the terms of the Creative Commons Attribution-NonCommercial License (BY-NC-4.0), <https://creativecommons.org/licenses/by-nc/4.0/>, which permits unrestricted noncommercial use, distribution, and reproduction in any medium, provided the original authors and source are credited.

**Funding:** None.

**Competing interests:** None.

**Authorship:** All authors have contributed significantly to this publication.

**Corresponding author:** Dr. Keshavamurthy Vinay, Department of Dermatology, Venereology and Leprology; Postgraduate Institute of Medical Education and Research, Sector 12, Chandigarh 160012, India. E-mail: [vinay.keshavmurthy@gmail.com](mailto:vinay.keshavmurthy@gmail.com)

## Case Presentation

A 28-year-old male sought consultation for asymptomatic lesions over abdomen since past 10 years. On examination, numerous, clustered, pigmented papules measuring 0.5 to 1 mm in diameter were present over abdomen (Figure.1A). Rest of the muco-cutaneous examination was within normal limits. Dermoscopy revealed multiple folliculocentric brownish-black structureless area surrounded by a prominent regular pigment network (Figure 1B). The intervening skin was normal. Based on the history and clinico-dermoscopic examination, a diagnosis of agminated acquired melanocytic nevus was made.

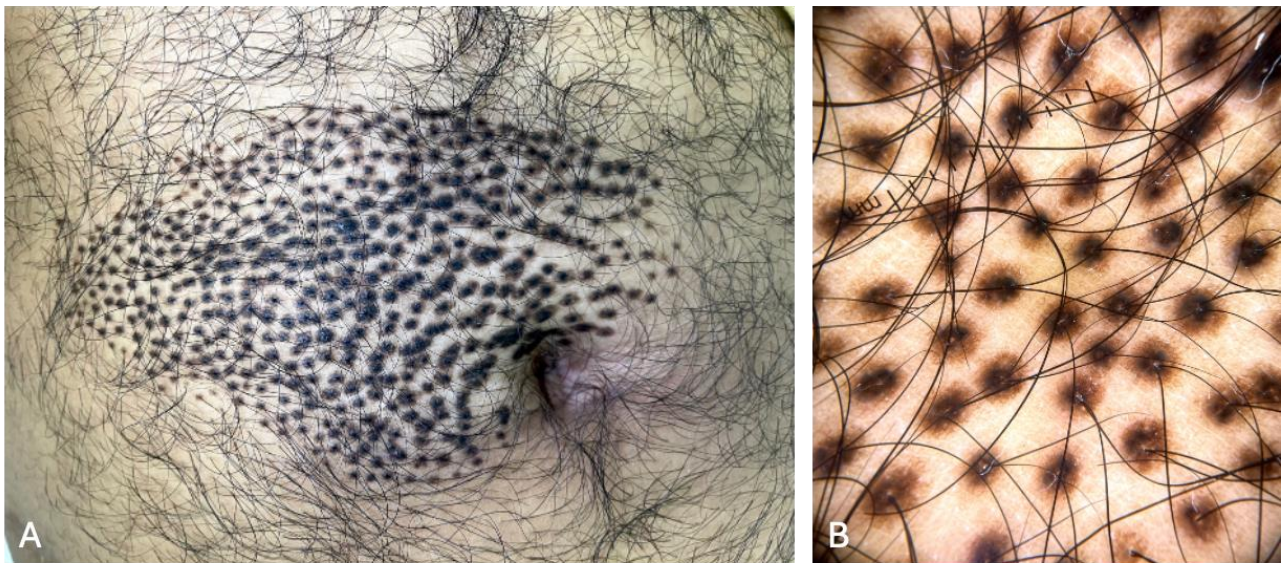
## Teaching Point

'Agminated' is derived from the Latin word 'agmen', meaning 'aggregation' and refers to a clustered or circumscribed grouping of lesions confined to a localized area of the body [1]. Agminated nevi is an infrequent presentation of melanocytic nevi.

Agminated patterns have been observed in several types of pigmented lesions, including Spitz nevi, blue nevi, lentigines, congenital melanocytic nevi, and acquired melanocytic nevi [2]. Vito Ingordo *et al* described a case of agminated nevi of the foot with checkerboard and blaschkoid distribution [2]. In our patient, the lesions were grouped over the peri-umbilical region. Dermoscopy revealed characteristically folliculocentric involvement with sparing of the intervening skin. Such arrangement led to a peculiar whorl appearance. Although, such lesions are benign, long-term follow-up with clinical and dermoscopic monitoring is recommended.

## References

1. Rocha CR, Grazziotin TC, Rey MC, Luzzatto L, Bonamigo RR. Congenital agminated melanocytic nevus--case report. *An Bras Dermatol*. 2013;88(6 Suppl 1):170-2.
2. Ingordo V, Licci N, Caccavale S, Ferrara G. Agminated Nevi of the Foot with Checkerboard and Blaschkoid Distribution. *Dermatol Pract Concept*. 2022;12(3):e2022110. Published 2022 Jul 1. DOI:10.5826/dpc.1203a110



**Figure 1.** A: Multiple clustered, pigmented papules measuring 0.5 to 1 mm in diameter over abdomen. B: On dermoscopy, multiple folliculo-centric brownish-black structureless area surrounded by a prominent regular pigment network. (3Gen DermLite DL4 Dermoscope, CA, USA×10 polarized mode).